

# **Surgical Management of Dystocia in a Persian Cat by Cesarean Section and Ovariohysterectomy**



**A clinical report submitted in partial satisfaction of the requirements for  
the Degree of Doctor of Veterinary Medicine (DVM)**

by

**Md. Omar Faruk**

**Roll No: 18/40**

**Reg No: 03000**

**Intern Id: 38**

**Session: 2017-18**

**Faculty of Veterinary Medicine**

**Chattogram Veterinary and Animal Sciences University**

**Khulshi, Chattogram-4225**

# **Surgical Management of Dystocia in a Persian Cat by Cesarean Section and Ovariohysterectomy**



Approved by

---

**Dr. Himel Barua**  
Professor  
Department of Microbiology and Veterinary Public Health

**Faculty of Veterinary Medicine**  
**Chattogram Veterinary and Animal Sciences University**  
**Khulshi, Chattogram-4225**

## Table of contents

CONTENTS	PAGE NO
<b>List of figures...</b> .....	<b>IV</b>
<b>Abstract</b> .....	<b>1</b>
<b>Introduction</b> .....	<b>2</b>
<b>Case presentation</b> .....	<b>3-11</b>
Case Description .....	<b>3</b>
Case Diagnosis.....	<b>4</b>
Anesthetic protocol and Restraining.....	<b>5</b>
Techniques for surgical procedure .....	<b>6-10</b>
Post operative follow-up.....	<b>11</b>
<b>Discussion</b> .....	<b>12-13</b>
<b>Conclusions</b> .....	<b>14</b>
<b>References</b> .....	<b>15-16</b>
<b>Acknowledgement</b> .....	<b>V</b>

## List of Figures

<b>Figure Title</b>	<b>Page no</b>
<b>Figure 01:</b> Weight measurement of the patient.....	<b>3</b>
<b>Figure 02:</b> A pregnant restlessness queen.....	<b>3</b>
<b>Figure 03:</b> Bloody vaginal discharge.....	<b>3</b>
<b>Figure 04:</b> X-ray reveals three fetuses.....	<b>4</b>
<b>Figure 05:</b> USG shows no fetal movement and heart beat.....	<b>4</b>
<b>Figure 06:</b> vomiting effect of Xylazine.....	<b>5</b>
<b>Figure 07:</b> General anesthesia by ketamine.....	<b>5</b>
<b>Figure 08:</b> Dorsal Recumbent position on OT Table.....	<b>5</b>
<b>Figure 09:</b> Shaving and scrubbing the surgical site for asepsis.....	<b>7</b>
<b>Figure 10:</b> Draping and incision caudal to umbilicus.....	<b>7</b>
<b>Figure 11:</b> Opening the surgical site and locate the uterus.....	<b>8</b>
<b>Figure 12:</b> Incision in uterine horn and removing fetuses.....	<b>8</b>
<b>Figure 13:</b> Ovary is ligated, transfixed and removed .....	<b>9</b>
<b>Figure 14:</b> Uterine body is removed by ligation and transfixation.....	<b>9</b>
<b>Figure 15:</b> Closing the internal site by specific suture techniques.....	<b>10</b>
<b>Figure 16:</b> Application of antiseptic and surgical tape on surgical site.....	<b>10</b>

## **Acknowledgment**

All of the praise is due to the Almighty ALLAH, the universe's creator and ultimate ruler, who made it possible for the author to finish the work.

The author expresses his sincere gratitude, humble respect, and immense debt of gratitude to his supervisor Professor Dr. Himel Barua of the Department of Microbiology and Veterinary Public Health at Chattogram Veterinary & Animal Sciences University for his leadership, gracious cooperation, sincere assistance, insightful suggestions, and constructive criticism, as well as for his active involvement in this study from its inception. The author also thanks and really respects all of his close companions and well-wishers for their encouragement and support throughout the study period and during the writing of this report.

Last but not least of all the author expressed his gratitude to all of his professors and parents for their enduring encouragement, advice, criticism, and friendly assistance from the beginning to the finish of his studies.

## **Abstract**

In domestic cats, cesarean section is a common procedure, especially in specific breeds that may have a higher risk of problematic births. Cats may experience dystocia, or difficult or lengthy labor, for a variety of reasons, which makes cesarean procedures essential to the reproductive health of felines. This study describes a case of dystocia in a Persian cat that underwent a cesarean section. A Persian cat was brought to the Teaching and Training Pet Hospital and Research Centre with indications of dystocia. The cat was incapable of giving birth to fetuses. Not only was the cat's abdomen visibly expanded, but it appeared depressed and had stopped eating with no signs of exerting itself. The radiographic examination revealed three fetuses. Later, the existence of three fetuses in the uterine horn was confirmed by abdominal ultrasonography (USG). On observation, fetal movements were found to be absent. A cesarean section was performed to remove three enormous, rotting dead kittens. In addition, an ovariohysterectomy was performed when it was found that the uterus was deteriorated and odorous. After the successful surgery the queen made a full recovery. A cesarean section followed by ovariohysterectomy was done to ensure a better risk-free life for the queen.

---

**Key words:** Cesarean section, Dystocia, Ovariohysterectomy, Persian cat

## Introduction

Following a typical gestation, animals undergo parturition, a distinct physiological event that marks the end of the pregnancy. Dystocia, also known as difficult parturition, is a condition in which the mother cannot expel the fetus on her own without medical assistance or surgery (Sahoo et al., 2018). Cats have a lower incidence of dystocia than large domestic or other pet animals (Jackson, 1999). There are several reasons associated with dystocia in animals. Fetal or maternal causes, or a combination of both, may be the cause of dystocia in cats (Stedile et al., 2011).

Dystocia is generally considered to be less common in small animals such as dogs and cats. According to a study, dystocia affects 3.3% to 5.8% of all births in cats (Pretzer et al., 2008). Maternal and fetal factors are the two primary causes of dystocia. Preterm birth can result from a number of factors, including small pelvic size, anomalies of the caudal reproductive system, primary or secondary uterine inertia, malnourishment, parasitism, uterine abnormalities, aberrant ejection due to non-uterine causes, and other maternal variables (Pretzer et al., 2008). Uterine inertia, or weak or nonexistent uterine contractions during parturition, is the most common cause of maternal dystocia (Raut et al., 2009). There are two categories for this condition: main and secondary inertia. Primary uterine inertia results from the uterine muscle's inability to contract adequately for a range of physiological or biological causes (Gendler et al., 2007).

The main treatment for pregnancy emergencies is medicine. Surgical intervention is recommended when medical therapy is unable to ameliorate the emergency situation. A study reported that 60–80% of bitch and queen dystocia instances require surgical intervention (Traas et al., 2008). The Cesarean section is performed to deliver kittens in queens with dystocia. The number of pets, primarily cats, has grown recently, and more cases of dystocia are being reported. However, there are not numerous case studies in Bangladesh that discuss surgical management for feline dystocia.

This case report describes the surgical management of dystocia by a cesarean section, which was followed by an ovariohysterectomy in a Persian cat, resulting in the removal of three dead fetuses.

## Case Presentation

### Case Description

A 1.0-year-old Persian queen cat weighing 2.60 kg (Figure 1) was brought to the Teaching and Training Pet Hospital and Research Centre (TTPHRC) on 10 October 2023 with a history of difficulty in parturition. Through natural mating, the cat completed her 65-day pregnancy. The cat was off-feed and showed signs of restlessness, panting and straining (Figure 2), and bloody vaginal discharge was seen (Figure 3). On observation, the cat appeared dull and depressed.



**Figure 1:** weight measurement of the patient



**Figure 2:** A pregnant Parsian queen with signs of restlessness and panting



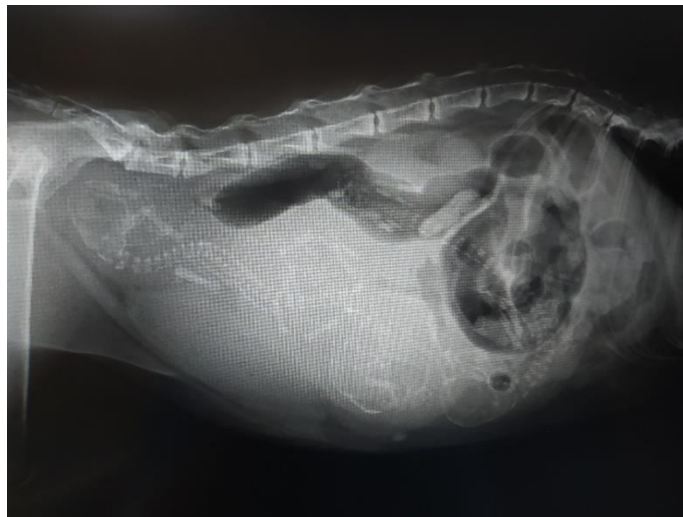**Figure 3:** Bloody vaginal discharge comes out from the Persian cat presented to TTPHRC



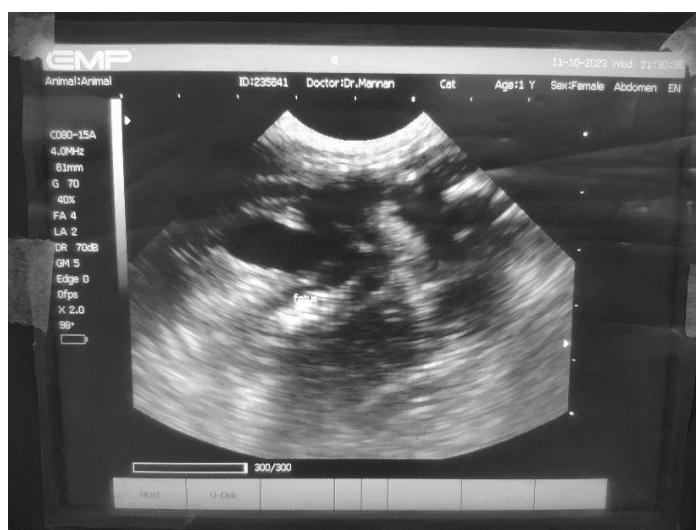## Case Diagnosis

**Clinical examination:** A clinical examination revealed elevated body temperature, fast breathing, and increased heart rate. Bony-like structures were felt on the left and right sides of the lower abdomen during the abdominal ballottement test.

**X-ray and ultrasonography findings:** Radiographic examination showed the presence of three fetuses (Figure 4). Later, both abdominal ultrasound (USG) and auscultation revealed the absence of a fetal heartbeat and fetal movement indicating fetal death (Figure 5). Following a USG, it was confirmed that uterine horn had three fetuses with no movement. The case was diagnosed as dystocia, and it was decided to remove the fetus through surgical intervention.



**Figure 4:** Three fetuses as revealed by X-ray.



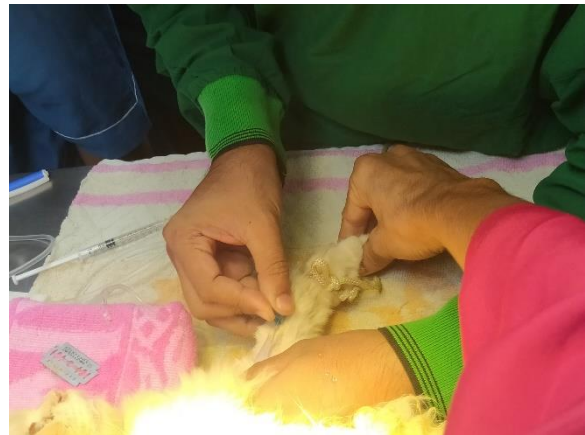**Figure 5:** USG shows no fetal movement and heart beat

## Anesthetic protocol and restraining

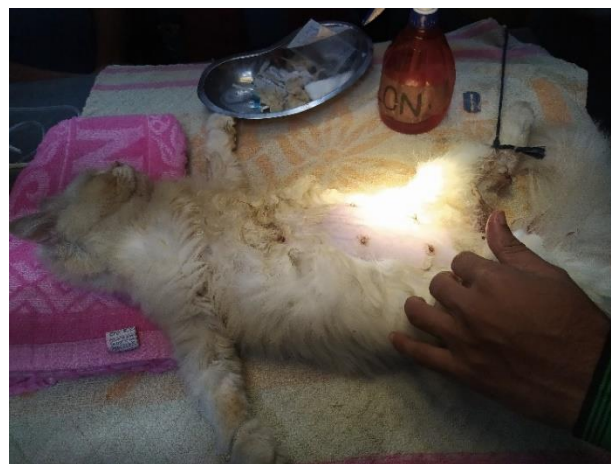The pre-anesthetic medication Xylazine Hydrochloride solution @ 1.2 mg/kg body weight (Inj. Xylazine, Indian Immunological Ltd. India) was first administered intramuscularly to the queen. Following administration of xylazine the queen vomited and a kidney tray was used in front of the queen for vomiting (Figure 6). After ten minutes, the cat was injected with ketamine hydrochloride intravenously at a dose of 8 mg/kg body weight (Inj. G-Ketamine, Gonoshasthaya Pharmaceuticals) to induce general anesthesia (Figure 7). Anesthesia was achieved in less than twenty minutes. The cat was then brought to the operating table, where it was placed in the dorsal recumbent position (Figure 8). This was done because a bigger bladder might make it more challenging to find and remove the uterus. After that, the limbs were secured with ropes. The tongue was pulled out to the side using forceps while the mouth was closed. An amount of 30 ml of 0.9% isotonic NaCl were given by vascular cannulation (I/V).



**Figure 6:** Vomiting effect of Xylazine



**Figure 7:** General anesthesia by ketamine



**Figure 8:** Dorsal Recumbent position on OT Table

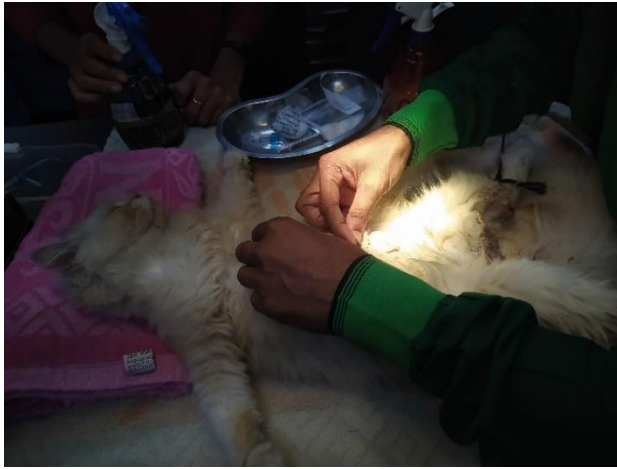## **Surgical Procedure**

**Surgical site preparation:** Aseptic surgery was performed on the animal to prevent microbes from entering the operation room. Two or three rounds of cutting, shaving, and sterilizing the operating area with 70% alcohol and 10% povidone iodine were conducted (Figure 9). A clean drape was placed over the operative site with the help of a towel clamp.

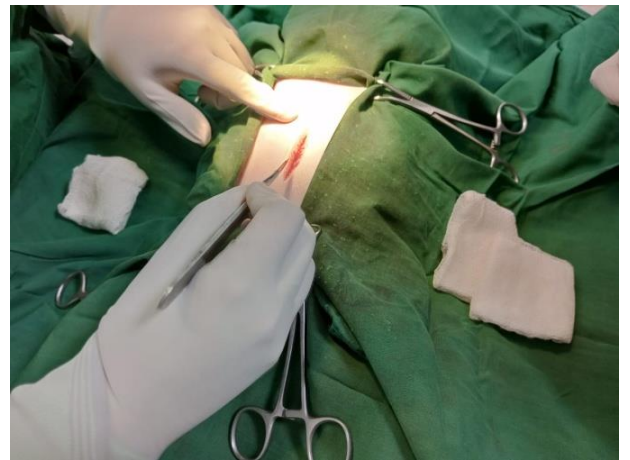
**Surgical procedure:** A 4–5-centimeter laparoscopic midline incision was made 2-3 cm caudal to the umbilicus (Figure 10). Subsequently, the peritoneum, linea alba, skin, and subcutaneous tissue were incised. The bleeding was checked by applying gauge pressure. The uterus was identified using a finger, and then it was taken out of the cavity (Figure 11). One uterine horn contained a single fetus and the other contained two fetuses. The uterine horns were incised to bring out the fetuses (Figure 12). Using an arterial forceps to grasp the left ovary, a distant vessel was closed off. After that, the ligature's attachment to the ovary was cut (Figure 13). The similar procedure was followed in case of right ovary. Vicryl 2-0 suture material was used to ligate and transfix the ovary.

After that a strong ligature around the uterine body was made by same suture material. The uterus was freed from its connection by crushing the surrounding tissues, including the mesovarium and mesometrium, with sterile scissors and sterile artery forceps (Figure 14). The ovariectomy procedure was performed for a 1 cm cranial to separation between the uterus and the cervix. The crushing stopped the bleeding. Before closing the abdominal wound, any symptoms of bleeding were checked.

The peritoneum, muscle, and subcutaneous tissue were sutured using simple continuous sutures with same suture material, and the skin was closed by putting a subcuticular suture (Figure 15). Next, sterile surgical tape and povidone iodine cream were used to properly secure the suture site (Figure 16).

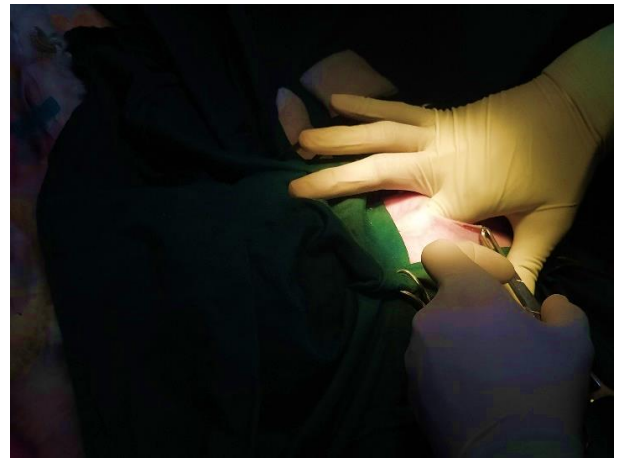
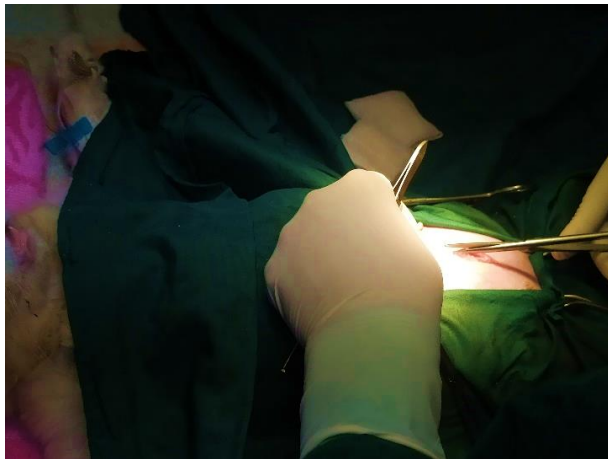


**Figure 9:** Shaving and scrubbing the surgical site for asepsis

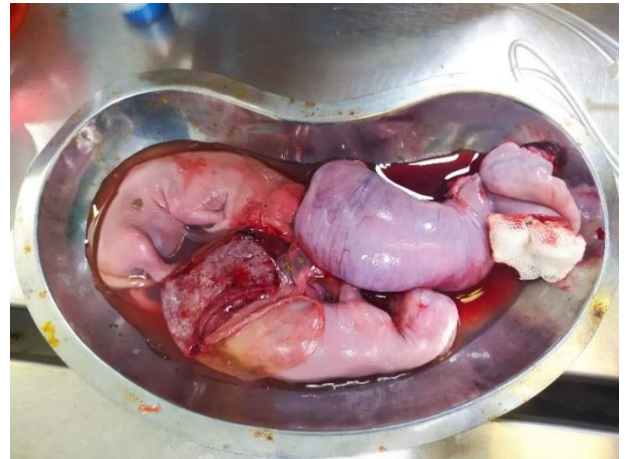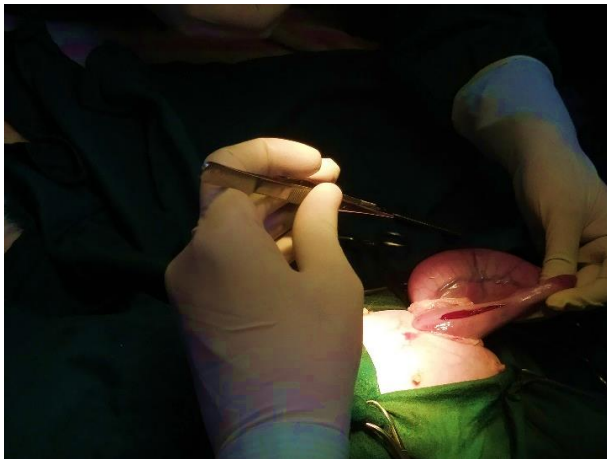


**Figure 10:** Draping and incision caudal to umbilicus

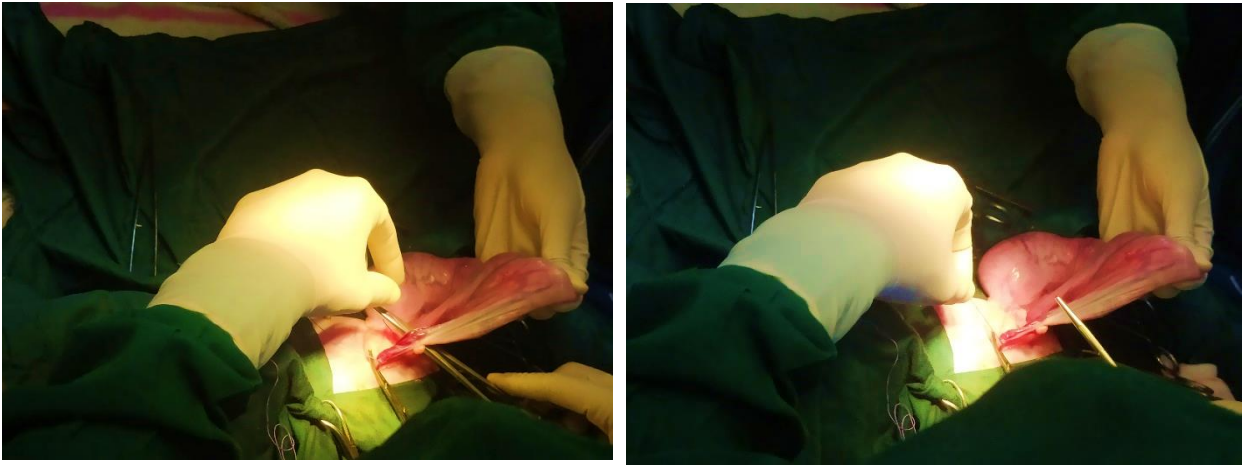




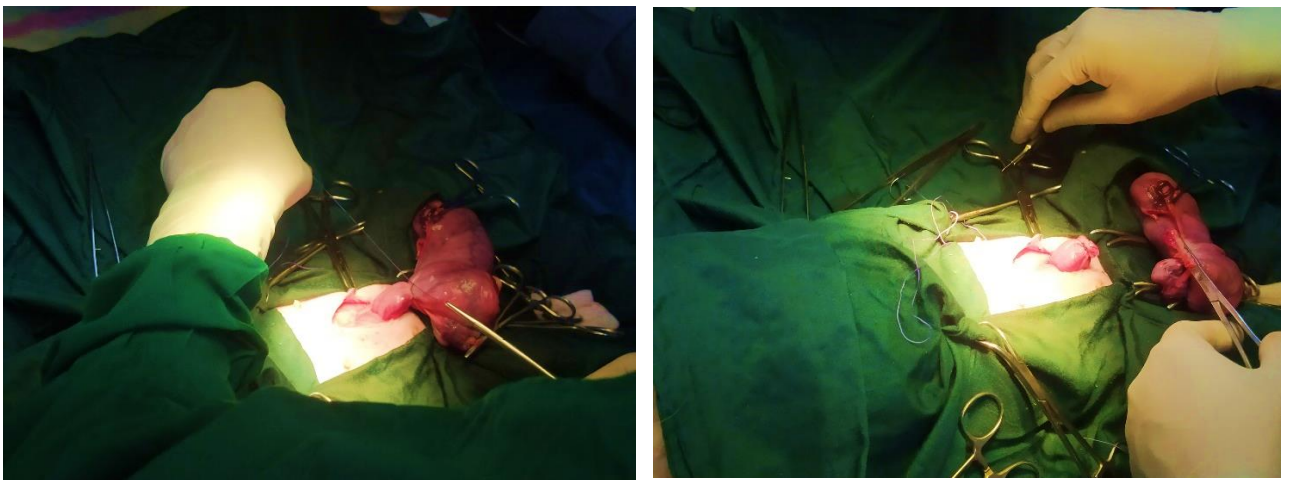
**Figure 11:** Opening the surgical site and locate the uterus with the help of finger



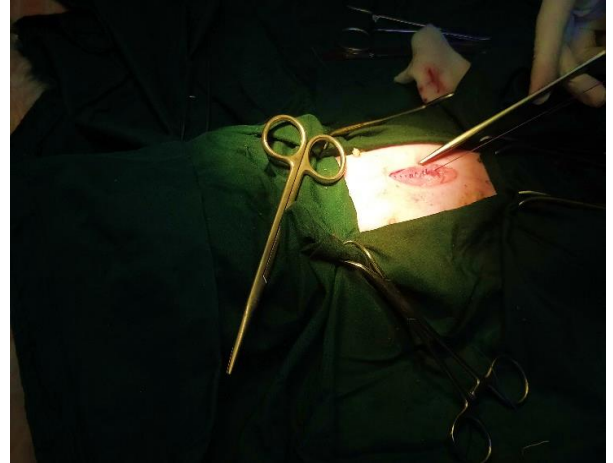
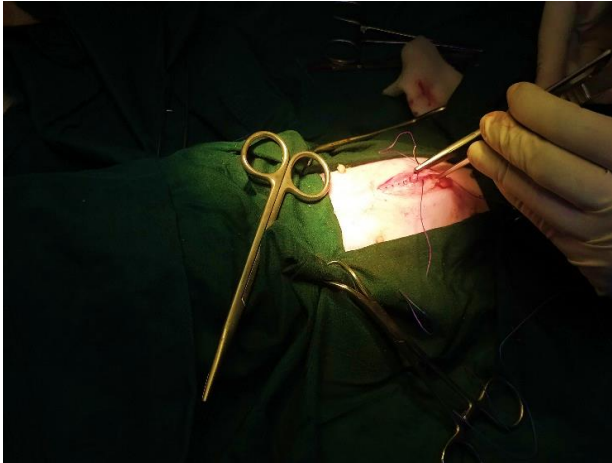
**Figure 12:** Incision in uterine horn and removing three fetuses



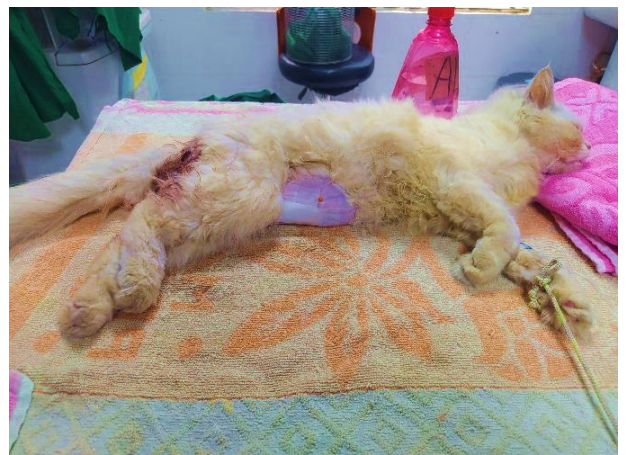
**Figure 13:** Ovary is ligated, transfixed and removed



**Figure 14:** Uterine body is ligated, transfixed and removed



**Figure 15:** Closing the internal site by specific suturing techniques



**Figure 16:** Application of antiseptic and surgical tape on the surgical area

## **Post operative follow-up**

To prevent infections, antibiotics were used following surgery. After the procedure, a daily dosage of 50 mg/kg body weight of the injectable antibiotic ceftriaxone was administered (Inj. Trizon Vet 1gm, ACME Laboratories Limited, Bangladesh) and injectable pheniramine maleate, antihistaminic, at a dosage of 1 mg/kg body weight (Inj. Phenadryl vet, ACME Laboratories Limited., Bangladesh), was given for seven days. Medications such as non-steroidal anti-inflammatory medications (NSAIDs) have the potential to lower edema and inflammation, hasten healing, and lessen discomfort following surgery. To control discomfort, 0.2 mg/kg body weight of meloxicam (Inj. Melvet, ACME Laboratories Limited, Bangladesh) was administered subcutaneously five days a week. In addition, 100 mg of vitamin C was given orally once a day for 15 days. Vital signs, which include heart rate, blood pressure, breathing rate, and temperature were continuously monitored in order to identify any early issues or anomalies following surgery.

**Advice and follow-up to owner:** The owner was suggested to keep the patient in a clean contamination free cage and to wear an Elizabethan collar over the neck to protect the surgical incision from being licked. The owner was advised to provide semiliquid food to the cat and careful about surgical site for licking and scratching by the queen. Following surgery, any problems like bleeding, infection, or negative anesthetic or drug responses were identified and treated early on with the help of post-operative care. In order to support healing and recuperation, post-operative care included dietary recommendations and optimal nutrition. The owner was suggested to maintain cleanliness in the region and keep surveillance out for any infections. The patient received treatment, care, and monitoring to guarantee a speedy and complete recovery. On the fourteenth day of post-surgery, the surgical site had fully healed, and the sutures were removed.



## Discussion

In this case, a Persian cat gave birth to three dead fetuses during a C-section. The cat went back to its regular routine of eating, drinking, playing, and urinating. The uterus was removed after an ovariohysterectomy in order to examine its inside. Three deceased fetuses were present. The fetuses seemed to be greater in size. The uterus was emitting a repulsive smell. The fetuses' and uterine wall's color clearly suggested that the uterus was afflicted with gas-forming bacteria. In dogs and cats, a rare illness known as emphysematous pyometra occurs when the uterus gets infected with gas-forming bacteria, leading to an accumulation of gas and infectious exudate in the uterine lumen. Emphysematous pyometra instances included the presence of *Staphylococcus* species, *Pseudomonas aeruginosa*, *Citrobacter diversus*, *Clostridium perfringens*, and *Enterococcus* spp. (Mattei et al., 2018). Cats are less likely than other animals to get dystocia (Talukder et al., 2021). According to Stedile et al. (2011), maternal or fatal causes account for the majority of feline dystocia cases.

The ventral midline incision is most commonly used for cesarean section. It is noteworthy that cats have been seen to physiologically extend the time it takes to give birth by up to 48 hours (Jutkowitz, 2005; Sparkes et al., 2006). In the current case, the queen was unable to deliver. The cat was tired, not trying at all, and not reacting to medicine when she was brought to the hospital. An ultrasound scan also showed no fetal activity. This implied that the fetus had passed away. Maternal toxemia has also been associated with anorexia, vaginal discharge with an unpleasant odor, dullness, and depression. It was decided to do an emergency C-section on the deceased fetuses for all of these reasons. The physical condition of the mother and the duration of her dystocia largely determine the outcome of a C-section.

In this case, a C-section was performed 24 hours after the onset of dystocia; yet, it was an effective method of removing three deceased fetuses, preserving the life of the mother. The deceased fetuses seemed significantly bigger due to gas accumulation in the subcutaneous tissue (emphysematous syndrome), which may also be associated with bacterial infections.

A strong uterine infection was strongly recommended during the surgery based on the color of the uterus and the foul stench coming from it. Therefore, the uterus and two ovaries were removed in order to prevent the development of toxemia and septicemia.

Pyometra, a potentially fatal uterine illness that can strike unspayed cats, is avoided by spaying them. Spayed cats often have longer lifespans than unspayed ones. This is perhaps because there is a lower chance of developing some diseases and disorders. A C-section is a surgical procedure, usually carried out while the patient is anesthetized. It's a serious decision that's often made when a normal birth puts the mother's or the kittens' health and wellbeing in danger. It is very important to perform C-section in that queen to save its life because three dead fetuses inside it creates much discomfort and a life risk situation. After the surgery the queen got comfort and having a risk-free life by ovariohysterectomy. So, successfully removal of three dead fetus by C-section was performed.

## **Conclusion**

A cesarean section followed by an ovariohysterectomy was carried out effectively in a Persian cat with dystocia. The queen's life was saved because of this C-section, which enabled the delivery of three dead kittens. It is crucial to remember that, even while a C-section can save a patient's life in specific circumstances, it is still a serious surgery with unique risks and recovery requirements. A C-section may need to be done right away in an emergency to protect the mother. C-section followed by ovariohysterectomy was followed to minimize the further risk and ensure the better long life of the queen.

## References

- Gendler, Brouman, J. D. & Graf, K. E. (2007). Canine dystocia: Medical and surgical management. *Compendium: Continuing Education for Veterinarians*. 29. 551-562.
- Jackson, P.G., 1995. Postparturient management. *Handbook of veterinary obstetrics*. 2<sup>nd</sup> Edn. WB Saunders. pp. 374
- Jutkowitz L. A. (2005). Reproductive emergencies. *The Veterinary clinics of North America. Small animal practice*, 35(2), 397–vii. <https://doi.org/10.1016/j.cvsm.2004.10.006>
- Mattei C, Fabbi M, Hansson K. 2018. Radiographic and ultrasonographic findings in a dog with emphysematous pyometra. *Acta Veterinaria Scandinavica*. 60(1): 1-5.
- Pretzer S. D. (2008). Medical management of canine and feline dystocia. *Theriogenology*, 70(3),332–336. <https://doi.org/10.1016/j.theriogenology.2008.04.031>
- Raut, B. M., Dhakate, M. S., Upadhye, S. V., Khan, L. A., Khante, G. S., Tiple, A.V., & Donekar, M. N. (2009). Uterine inertia in bitch. *Veterinary World*, 2(2), 71.
- Sahoo AK, Nath H, Nahak A, Behera SS, Parija D, NayakS. 2018. Surgical management of dystocia due to secondary uterine inertia in dog-case report. *EC Veterinary Science*. 3(1): 260-265.
- Sparkes, A. H., Rogers, K., Henley, W. E., Gunn-Moore, D. A., May, J. M., Gruffydd-Jones, T. J., & Bessant, C. (2006). A questionnaire-based study of gestation, parturition and neonatal mortality in pedigree breeding cats in the UK. *Journal of feline medicine and surgery*, 8(3), 145–157. <https://doi.org/10.1016/j.jfms.2005.10>
- Stedile R, Oliveira ST, Muccillo MDS, Contesini EA, Beck CDC. 2011. Dystocia in a cat due to an ectopic artery. *Veterinary Record*, 169(21):10-1136.

Stedile R, Oliveira ST, Muccillo MDS, Contesini EA, Beck CDC. 2011. Dystocia in a cat due to an ectopic artery. *Veterinary Record*, 169(21):10-1136. Talukder AK, Das ZC, Rahman MA, Rahman MT, Rahman AN. 2021. Caesarean section followed by ovariohysterectomy in a Bangladeshi domestic cat: A surgical intervention for management of dystocia due to partial primary uterine inertia. *Veterinary Medicine and Science*. 7(5): 1564-1568.

Traas, A. M. (2008). Surgical management of canine and feline dystocia. *Theriogenology*, 70(3), 337–342. <https://doi.org/10.1016/j.theriogenology.2008.04.014>