

Abstract

The present case report highlights the imperil effect of effusive form of feline infectious peritonitis (FIP) in the cat's population. Feline Infectious Peritonitis Virus (FIPV) is the causative agent of FIP. In cat's high fever, anorexia, weight loss and ascites are primary clinical signs associated with FIP. The study was being carried out at Teaching and Training Pet Hospital and Research Centre (TTPHRC) A similar case was presented at veterinary teaching hospital. Diagnosis was made on the basis of clinical signs, history, positive Rivalta test, complete blood count (CBC) and serum biochemistry findings including neutrophilic leukocytosis, lymphopenia and hyperglobuliemia, elevated liver enzymes and blood urea nitrogen, respectively. Fluid therapy (5% dextrose saline and 0.9% saline), diuretics (frusemide), proton pump inhibitor (pantoprazole/esomeprazole), antibiotics (ceftriaxone or metronidazole and ceftriaxone) and multivitamins can be used as the supportive treatment for the disease. Vaccination in proper age is strongly suggestive to prevent the disease

Chapter 1: Introduction

Feline infectious peritonitis (FIP) is highly fatal viral disease of domestic and feral cats (Pederson, 2009). Feline infectious peritonitis virus (FIPV), the causative agent of FIP belongs to feline corona virus (FCoV) biotype 1. FCoV is RNA, single stranded, positive sense, enveloped virus belonging to Coronaviridae family (Lewis et al., 2015). Coronaviruses are a family of viruses that chiefly cause respiratory infections. The disease is seen worldwide. Although a large number of cats may be infected with the feline coronavirus, only a few develop the severe form of the disease. It is unknown why only certain cats are affected, but it is thought that a mutation within the virus and an inappropriate immune response by the individual cat may be responsible. Cats of all ages and either sex can develop feline infectious peritonitis, but the disease is most frequent in cats 6 months to 2 years old. Although the disease can occur in any breed, purebred cats (including Persian, Abyssinian, Bengal, Birman, Himalayan, Ragdoll, and Rex breeds) are most likely to be affected. Kittens raised in infected colonies may contract the virus from their mothers or from carriers (infected cats with no obvious signs of disease) when their maternal immunity decreases at 5 to 6 weeks of age.

Most infections probably result from ingestion of the virus. Transmission by inhalation is also possible. Because cats shed particles of the virus in feces, litter box exposure is the most important source of infection. The virus can also be transmitted through saliva, by mutual grooming, sharing the same food bowl, sneezing, and through close contact. Cats living in multiple-cat households are at greater risk of the disease. It has been suggested that this disease can move across the placenta from mother to developing kitten; however, the frequency with which this occurs is unknown.

Following entry of FCoV into body through feco-oral route, the virus multiplies into the epithelial cells of intestine leading to development of diarrhea, which is usually seen due to feline enteric corona virus (FECV). Both FECV (nonlethal) and FIPV (lethal) could be present at the same time inside the body; however mutation of FECV can also occur into FIPV at any time. Several factors such as signalment, any stress, immune status, steroid therapy and concurrent infection play a significant role for viral mutation. The mutated virus is phagocytized and starts replicating in the macrophages and lymph nodes, spread throughout the body via blood circulation, attract antibodies, makes antigen-antibody complex leading to release of vasoactive substances and protein rich fluid in peritoneal and abdominal cavity that contributes towards the development of classical signs of disease (Pederson, 1995). Generally there are two types of FIP, one is wet or effusive form characterized by immune mediated excessive accumulation of inflammatory exudates in the body cavities and other is dry or non-effusive form, characterized by

presence of granulomatous or pyogranulomatous lesions especially in the, mesenteric lymph nodes, liver, kidney, bowel wall, CNS and eyes (Montali and Stranberg., 1972).The signs of feline infectious peritonitis vary depending on which organs are involved. Many organs, including the liver, kidneys, pancreas, CNS, and eyes, can be affected. The length of time between infection and mutation of the virus and development of signs varies between cats. Affected cats may be alert or depressed. Some eat with a normal or even increased appetite; others refuse to eat. Fever, weight loss, and/or jaundice may be noted. Some cats have noticeable fluid build-up in the abdomen causing it to look distended. About one-third of cats with effusive disease have lung involvement and difficulty breathing. Fluid may also accumulate around the heart.

Cats without obvious fluid build-up usually have a history of vague illness. This includes repeated fever, malaise, weight loss, and occasionally organ failure (most often the kidneys or liver).Involvement of the eyes and central nervous system is common and may occur either simultaneously or independently of other signs. When the eyes are affected, there may be bleeding or accumulation of pus in one or both eyes. Other ocular changes, including blindness, can also occur. The most common sign of nervous system involvement is poor coordination of muscles with slight paralysis progressing to generalized failure of muscle coordination. Convulsions (seizures), tremors, personality changes, and increased sensitivity to touch may also be seen.

FIP falls among the leading infectious causes of death in young cats from shelters and catteries. This disease is distributed throughout the world. In the United State, it is most commonly seen disease of cats. Generally, seroprevalance of FECV is reported to be 80-90% in catteries living cats, while up to 50% in companionless cats (Simons et al., 2005). There is no specific treatment as it is a viral disease. Some supportive and symptomatic treatment has been recommended like antibiotic to control the secondary bacterial infection, combating dehydration, and nutritional supplement etc. (Truyen et al., 2009). As it is a highly fatal disease, vaccination should be done to prevent the disease. The commercially available vaccines for FPV virus include the modified live virus or an inactivated virus vaccine. Two injections, at 8–9 weeks of age and 3–4 weeks later, are recommended, and a first booster 1 year later (Truyen et al., 2009). Supportive therapy and good nursing significantly decrease mortality rates. Domestic cats, young ages, immune suppressed cat, multi-cats in households, aggressive and male cats are highly susceptible for feline infectious peritonitis. FIP is most likely to occur in cats younger than 1 year of age. But it can occur in unvaccinated or improperly vaccinated cats of all ages. The median age of affected cats in one study was 4 months, and when disease occurred in vaccinated cats, it occurred only in cats that had not received a booster vaccine after 12 weeks of age. However, kitten

deaths have been reported in households of fully vaccinated kittens, possibly because of exposure to large amounts of virus in the environment. Outbreaks of FIP in cats correlate seasonally with increases in susceptible newborn kitten numbers. FIP occurs most commonly in multicat households, and especially in enclosed, shelter environments. It can also occur in cats with outdoor exposure, such as barn, feral, and stray cats (Kruse et al., 2010).

As it is a highly contagious and fatal disease for cat, the detail study regarding the disease is important to prevent and control the disease. As per our knowledge, very few studies especially based on treatment practices and vaccination status for feline infectious peritonitis in cats is scarcely documented in Bangladesh

The present case report is mainly focused on diagnosis, treatment and prevention of FIP. The present study was undertaken with the following objectives:

1. To estimate the prevalence of FIP in cats.
2. To know the frequency of different factors like age, breed and sex etc. in FIP
3. To understand the frequently occurred clinical signs in the disease.
4. To get an idea about the therapeutic practices for the diseases

Chapter 2: Materials and methods

2.1 Study area:

Bangladesh's first-ever pet animal hospital, Teaching and Training Pet Hospital and Research Centre, which was started its journey on October, 2018 in Dhaka's Purbachal area. The hospital is regulated by Chattogram Veterinary and Animal Sciences University (CVASU). The hospital was set up for providing hands-on training to interns and postgraduate veterinary doctors. It has a well-equipped operation theater, x-ray, ultra-sonogram and laboratory facilities. It provides different services like treatment, vaccination, deworming, health check-up and surgery etc. to both pet animals and birds. Additionally, exotic and zoo animals are brought here for treatment and health checkup. So, it is a good source of different clinical cases of pet animals.

2.2. Data and information collection:

After initial registration and history taking each case was being undergone for clinical examination. Clinico-epidemiological findings of each case were being recorded in the structured record keeping sheet. Data included address, date, total population, housing system, species, breed, age, sex, body weight, BCS, vaccination, de-worming, previous disease history with treatment, duration of illness, defecation, micturition and vomiting along with client demographic information (age, sex, education and job). Pulse, respiration, rectal temperature were being taken; skin fold test, examination of mucous membrane and different organs of the body were being performed by using the methods of palpation, percussion and auscultation. Diagnosis and drug prescription data were also being recorded in the structured record keeping sheet. Drug data made up with trade name of the drugs, main and supportive drugs, dose, route and duration.

2.3. Case Description

A 1.5 year old domesticated short haired female cat weighing about 4kg was presented at for the evaluation of 10 days history of recurrent ascities, lethargy, anorexia and polydipsia. Clinical examination revealed dehydration, anemia, mild nasal discharge and ascities. Temperature, respiration and heart beat were respectively 104°F, 30 breaths/minute and 140 beats/minute, respectively. A complete blood count (CBC) and serum biochemistry profile

revealed neutrophilic leukocytosis, anemia and hyperglobuliemia, respectively. She was treated with fluid therapy, antibiotic along with steroid and discharged with the advice to continue this treatment for next 4 days

2.4. Diagnosis protocol

FIP occurs most often in young cats under two years of age. Male cats and certain breeds are suggested to be overrepresented. Clinical signs, such as anorexia, lethargy, weight loss, pyrexia, ocular and neurological signs like gait abnormalities or abnormal mentation, are non-specific. The same is true for clinicopathologic abnormalities. In general, tests using effusion have much better predictive values than tests using blood. Thus, ante mortem diagnosis of FIP is especially difficult in cats without significant effusion. Since a definitive diagnosis cannot be made based on signalment, history and clinical and laboratory signs alone, these parameters should always be evaluated as an entity and potentially in conjunction with other parameters, such as results of molecular or even more invasive diagnostic tests. In order to avoid falsely diagnosing FIP in unaffected cats, specificity is always the most important diagnostic value to consider.

2.4.1 Clinical signs:

Early signs of FIP can vary but often include a rising and falling fever, loss of appetite, and energy loss. As time goes by, infected cats may have more FIP symptoms that depend on the form of FIP.

FIP comes in a "dry" form and a "wet" form. Infected cats can have symptoms of only one form or a combination of both.

Dry form: The dry form of FIP causes infection and inflammatory lesions around the blood vessels in a cat's body. This infection can affect the brain, liver, kidneys, lungs, and skin. This form often causes the cat to have seizures and move in an abnormal or uncoordinated way. In some cases, cats will also have excessive thirst and urination, vomiting, weight loss, and jaundice.

Wet form: With this form of the disease, fluid builds up in the abdomen, which causes a pot-bellied appearance. Fluid may also build up in the chest, making it hard for the cat to breathe. This form of FIP causes damage to the blood vessels, resulting in inflammation and fluid leaking from the blood into the abdomen and chest.

2.4.2. Blood Test:

Hematological abnormalities are very common in cats with FIP. Reported changes mainly include anemia (non-regenerative as well as regenerative anemia can be present, e.g., immune-mediated hemolytic anemia has been reported), microcytosis with or without anemia, lymphopenia (more commonly in cats with effusion), band neutrophilia (with or without segmented neutrophilia) and thrombocytopenia. Whereas microcytosis and band neutrophilia are common features of FIP in general, lymphopenia, observed in about 50% of cats with FIP, can be seen significantly more commonly in cats with effusion, but is reported only rarely in cats without effusion. The vast majority of cats with FIP also have abnormalities upon serum biochemistry. In particular, hyperproteinemia, and especially hyperglobulinemia (that can also be present without an increase in total serum protein), hypoalbuminemia (more common in cats with effusion), hyperbilirubinemia (more common in cats with effusion) and potentially, depending on organ involvement, azotemia (detected more often in cats without effusion) or increased liver enzyme activities can be present. The most common abnormality reported is hyperglobulinemia, documented in about 89% of cats with FIP. These changes can occur in variable combinations but it is important to note that they absolutely are neither pathognomonic nor specific for FIP, meaning that they can occur in any cat suffering from various diseases with an inflammatory basis, which represent differential diagnoses for FIP. Hyperglobulinemia in cats with FIP can occur either alone or in combination with hypoalbuminemia or hyperproteinemia. Although it has been suggested that the albumin to globulin (A:G) ratio has better diagnostic utility than the gamma-globulin or total protein concentration alone and several cut-offs have been suggested to potentially rule in (<0.4) or rule out (>0.6–0.8) FIP, the A:G ratio, as other hematological and serum biochemistry changes, should only be interpreted in conjunction with signalment, history, other laboratory parameters and possibly molecular diagnostic methods. Elevated gamma-globulin concentrations can be either polyclonal (more common) or monoclonal as differentiated by serum protein electrophoresis. Thus, if a cat presents with any of the aforementioned clinicopathologic abnormalities in routine practice, these always have to be interpreted in conjunction with other clinical, laboratory or imaging findings. They might only support a suspicion of FIP if other abnormalities consistent with FIP are present as well and FIP should never be diagnosed solely on the basis of hematological or biochemical parameters.

Cats with FIP often exhibit markedly increased concentrations of acute phase proteins (APP), such as alpha-1-acid glycoprotein (AGP), serum amyloid A (SAA) or haptoglobin in serum. Still, although these parameters can help in establishing a diagnosis and a negative AGP measurement can potentially exclude FIP, on their own, they are not pathognomonic for FIP. Increased concentrations of APP can also be found in cats with various other inflammatory conditions, neoplasia or even in healthy FECV-infected cats. As was stated before for hematological and serum biochemical parameters, measurement of APP, such as AGP, can only be helpful when interpreted together with other abnormalities in order to provide an index of suspicion of FIP in an individual cat.

2.4.3 Effusion:

The majority of cats with FIP present with effusion—specifically, pleural effusion, ascites or a combination of both. Even cases of pericardial effusion have been reported. The typical fluid from a cat with FIP is viscous, straw-colored, clear to moderately cloudy and usually forms clots or strings because of its high protein content. Macroscopic and cytologic examination of those effusions and determination of cell count and biochemical parameters is important in order to exclude or confirm other differential diagnoses (such as lymphoma by cytology or bacterial peritonitis or pleuritis by cytology and bacterial culture); but again, changes are not specific for FIP. Although typical effusions from cats with FIP have a high protein content, low A:G ratio and rather low total cell count these findings can also occur in effusions of other etiologies (Lorusso, E. *et al*). Nevertheless, in a cat which presents with typical signalment, clinical and routine laboratory abnormalities (such as for example a young cat with fever, icterus, anemia, hyperglobulinemia) and effusion, effusion analysis including cytology and bacterial culture, although not completely specific for FIP, can exclude other conditions that could confound the diagnosis and can at least help in increasing the pre-test probability for FIP.

The Rivalta's test is a cheap and quick test that can easily be performed on effusions in clinical practice, which is why, in the authors' opinion, it should be included in the diagnostic protocol in every cat with effusion. It has good sensitivity for excluding FIP (91–100%), meaning that whenever it is negative, other potential causes for effusion are much more likely than FIP. Therefore, especially if financial concerns limit the number of diagnostic tests that can be performed, the Rivalta's test can at least be used to exclude FIP with satisfying

negative predictive value with the advantage of no need for any automated analysis. However, its specificity was reported to be only 66–81%. Since the Rivalta's test is positive most likely secondary to increased amounts of protein and inflammatory mediators in a fluid, it was originally used to differentiate transudates and exudates, and therefore can also be positive in effusions caused by bacterial peritonitis/pleuritis or lymphoma. These conditions, however, can usually easily be diagnosed by routine cytology and culture of the effusion, which should also always be performed when analyzing an effusion sample.

Another test that relies on the abundance of proteins in effusions from cats with FIP is the measurement of the delta total nucleated cell count (Δ TNC) in an automated hematologic analyzer (Sysmex XT-2000iV, Sysmex Europe, Norderstedt, (Denmark), measuring leucocytes in two different channels. The ratio between both channels, the Δ TNC, is higher in cats with FIP than in healthy cats, and its measurement showed quite good diagnostic accuracy. Using a cut-off of 1.7 for Δ TNC, diagnostic sensitivity of the method was 79–90%; specificity was 94–100%. Higher cut-offs of 2.5 or 3.4 even increased specificity to 100%.

2.4.4. Aqueous Humor

In cats without FIP that do not present with effusion, uveitis is common and ocular signs (with or without involvement of the central nervous system) can be noticed in 60% of the affected cats. Secondary to the inflammation of ocular structures and breakdown of the blood-ocular barrier, FCoV-bearing macrophages are present in the eye and FCoV antigen can be detected immunocytochemically within macrophages in the aqueous humor. The results of the only prospective study that evaluated ICC in aqueous humor in cats with immunohistochemically confirmed FIP and control cats with similar clinical signs but histopathologically diagnosed other diseases are depicted in. The technique only has a moderate sensitivity and specificity for the diagnosis of FIP, and therefore, it cannot be used as a single confirming diagnostic test.

Table.1 Complete blood count (CBC)

Parameters	Presenting value	Reference Values
Red blood cells (RBC) (g/L)	4	5-10
Packed cell volume (PCV) (%)	27.5	30-45
Hemoglobin (Hgb) (g/dL)	5	8-15
Mean corpuscular volume (MCV)	60	39-55
Mean corpuscular hemoglobin (MCH) (pg)	19	13-17
Mean corpuscular hemoglobin concentration	24	30-36
White blood cells (WBC)	25	5.5-19.5
Neutrophils (%)	90	35-75
Lymphocytes (%)	8	20-55
Monocytes (%)	1	1-4
Basophils (%)	0	0-1
Eosinophils (%)	1	2-12

(Reference values, from The Merk Veterinary Manual 9th edition)

Table.2 Serum biochemistry

Parameters	Presenting Values	Reference Values
AST (μ/L)	43	9.2-40
ALT (μ/L)	25	8.3-53
Albumin (g/dL)	1	2.4-3.8
Globulin (g/dL)	10	2.4-3.7
Alkaline Phosphatase (μ/L)	45	9.2-40
Creatinine (mg/dL)	4	0.5-1.9
Blood Urea Nitrogen (mg/dL)	38	15-30

(Reference values, from The Merk Veterinary Manual 9th edition)

Chapter 3: Treatment, Prevention and Control

Here is no specific treatment for feline infectious peritonitis. Although recovery from signs has been reported, it is uncommon. Up to 95% of cats with feline infectious peritonitis will die from the disease. In one study, half of the affected cats died within 9 days. However, some cats may live for several months.

Treatment with drugs that reduce inflammation and suppress immune reactions, along with supportive care, can make the cat more comfortable. In some cats (probably less than 10%), treatment may extend survival time by several months. Treatment offers the most hope for cats that are still in good physical condition, still eating, have not yet developed nervous system problems, and that do not have additional disease (such as feline leukemia virus infection). If a cat shows no improvement after 3 days of treatment, it is unlikely to improve. If the cat's quality of life is poor and treatment has not helped, euthanasia is often considered.

When a cat in a household develops feline infectious peritonitis, all in-contact cats will have already been exposed to the same virus. Fortunately, in most cases, in-contact cats will not develop the disease. (Recall that most cats that are infected with coronavirus never develop feline infectious peritonitis.) However, cats with feline infectious peritonitis should not have contact with any new cats, especially kittens that have not been exposed to the virus. In addition, if your cat died because of the disease, you should wait 2 months before obtaining another cat to be sure that the virus is no longer present in the environment.

A vaccine is available to help prevent feline infectious peritonitis. However, many adult cats will have been previously exposed to the virus, so vaccination will not prevent their infection. The vaccine is labeled for use beginning at 16 weeks of age, which may be too late to protect kittens in households where the virus is present. The American Association of Feline Practitioners lists the FIP vaccine as “not recommended.”

Vaccination alone cannot be relied on to control the disease within a cat facility. Other measures to reduce exposure include frequent removal of feces (the primary source of coronavirus), early weaning, and isolation of cats that test positive for coronavirus antibodies. Additionally, isolation and testing of cats after shows, proper sanitation and cleaning using

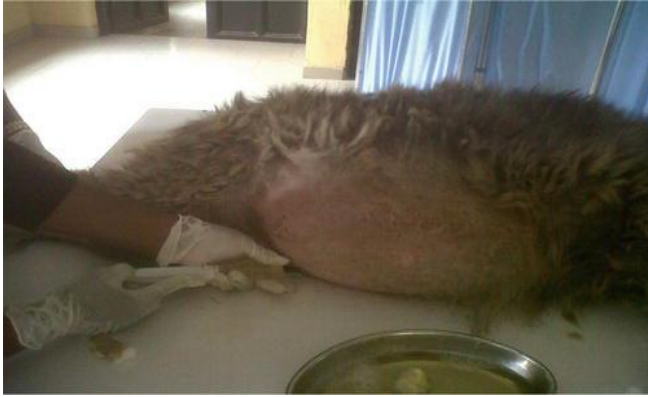viral disinfectants, and vaccination against other feline viruses can reduce exposure. These control measures should be combined with an overall preventive health program. However, in households or facilities with large numbers of cats, it can be very difficult to eliminate feline corona virus and, as such, there will be a risk for the development of feline infectious peritonitis.

Cats with FIP do not appear to be very contagious to cats that they come in contact with. Although this has been based mainly on clinical observations, it has also been confirmed by laboratory studies. We have not observed contact transmission in experimental settings. Furthermore, cat-to-cat transmission implies that every FIPV isolated from a group outbreak of FIP will be genetically identical in its 3c gene mutation. Horizontal transmission is theoretically possible, although very uncommon


Chapter 4: Discussion

FIP has been reported in all breeds of cats; however feral cats are less susceptible to infection. Although kittens, young cats and male are more susceptible to this disease, however any age group can be susceptible. The clinical signs in affected cat of this case study were fever, abdominal distension due to ascities and anorexia as previously described by Wolfe and Griesemeer (1966). Major findings of the complete blood count (CBC) at the time of presentation were leukocytosis especially neutrophilia and mild anemia (Table 1). Serum biochemistry analysis revealed hyperglobuliemia, increased liver enzymes and blood urea nitrogen (Table 2). Hartmann et al., (2003) described similar hematological and serum biochemistry findings in cats affected with wet form of FIP. Disease is present throughout the world affecting all breeds of cats however; the incidence of development of disease in the pure-breed cats is reported to be high because of lack of hybrid vigor. There is no effective treatment for FIP; disease can only be prevented by effective managemental strategies. If the affected cat becomes lifelong carrier then it will shed the same viral biotype throughout its life. Virus can remain active in fecal material up to 7-8 weeks which is potential source of infection for healthy cats in litter box, so proper disposal of fecal material along with keeping healthy cats away from infected litter box is effective preventive strategy. Reducing the population of cats, early weaning of new born kittens (Addie and Jarrett, 1990), keeping cats in separate cages, efficient hygiene and cattery design, careful selection of breeding male, screening of affected cats and vaccination are key elements to reduce incidence of the disease.

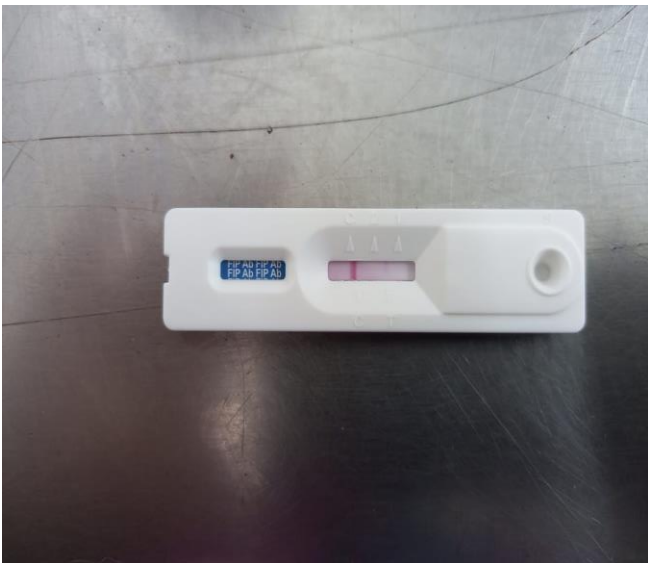
Figures



Ascites and removal of fluid



Positive Rivaltas Test



Rapid test kit

Acknowledgement

All praises are due to the immeasurable grace and immense kindness Of Almighty GOD, the supreme authority and supreme ruler of the universe, who has enabled me to accomplish this work.

I would like to express my deep sense of gratitude and thanks to my supervisor **Professor Dr. Md. RayhanFaruque**, Professor, Department of Medicine and Surgery, Chattagram Veterinary and Animal Science University, Whose encouragement and supports helps me for the completion of the report.

I express my sincere gratitude and thanks to **Professor Dr. MdAlamgirhossain**, dean of Veterinary Medicine, CVASU.

I would like to thank Professor **Dr. A. K. M. Saifuddin**, Director of external affairs for his supervision and co-operation during the period of internship.

I am profoundly grateful to my family for their endless sympathies, help, sacrifices and prayer.

The Author
November 2021

References

- Addie DD, Jarret O. (1990): Feline corona virus infections. In Infectious Diseases of Dog and Cat. Edited by Greene CE. Philadelphia: WB Saunders, 300-312.
- Hartmann K, Christina B, Johannes H, Dana C, Manfred R, Simone S, Jens F, Herman E, Hans L, Walter H. (2003) : Comparison of different tests to diagnose feline infectious peritonitis. *Journal of Veterinary Internal Medicine*, 17: 781-790
- Kruse, Sorum H, Tasker, S.(2010) : Transfer of multiple drug resistance plasmids between bacteria of diverse origins in natural microenvironments.
- Lewis, C. S., Emily porter, David Matthews (2015) :Genotyping coronaviruses associated with feline infectious peritonitis. *J. Gen. Virol.* **96** 1358.
- Montali RJ, Standberg JD. (1972): Extraperitoneal lesions in the feline infectious peritonitis. *Veterinary Pathology* 9:109-121
- Pederson NC. (2009): A review of feline infectious peritonitis virus infection. *Journal of Feline Medicine and Surgery*, 11: 225-228
- Pederson NC. (1995): An overview of feline enteric corona virus and infectious peritonitis virus. *Journal of Feline Practices*, 23: 7-20
- Simons FA, Vennema H, Roffina JE. (2005): AmRNA PCR for the diagnosis of feline infectious peritonitis. *Journal of Virology Methods*, 124: 11
- Truyen, Hoong L.W. ; Yasmin A.R. ; Mummooorthy, (2009); Molecular investigation of Feline Coronavirus (FCOV) in local pet cats. *J. Vet. Malaysia*. 31(2): 13-18.
- Wolfe LG, Griesemer RA. (1966): Feline infectious peritonitis. *Veterinary Pathology*, 3:255-270
- .

Biography



Intern Doctor, Veterinary Medicine

Chattogram Veterinary and Animal Sciences University

Email: paprychakrabortty@gmail.com

Personal Profile:

Name: PapryChakrabortty

Father's Name: JoyantoChakrabortty

Mother's Name: ProtimaChakrabortty

Permanent Address: Gaibandha

Nationality: Bangladeshi.

Religion: Hindu

Blood group: AB+

Academic Qualifications:

Name of the examination/ Course	Name of the institution	Board	Passing Year	Grade
SSC	Ahmed Uddin Shah School and Collage, Gaibandha	Dinajpur	2013	5.00
HSC	Ahmed Uddin Shah School and Collage, Gaibandha	Dinajpur	2015	5.00
DVM	Chattogram Veterinary and Animal Sciences University	CVASU	—	—