
TABLE OF CONTENTS

Contents	Page No
List of figures	i
Abstract	ii
Chapter 1: Introduction	01
1.1 General introduction and background	01
1.2 Objective	01
Chapter 2: Materials and Methods (Case Description)	02 – 04
2.1 Case history and description	02
2.2 Anesthesia and Control	02
2.3 Operation Procedure	02 - 03
2.4 Post Operative Treatment and Care	03
Chapter 3: Results and Discussion	04
Chapter 4: Conclusion	05
References	06
Acknowledgement	07
Biography	08

LIST OF FIGURES

Figures	Page no.
Figure A	6
Figure B	6
Figure C	7
Figure D	7
Figure E	8
Figure F	8

Abstract

The goal of this case study was to perform the usual surgical approach of cat spaying. During our internship, a local breed female cat, 8 months old and weighing 2.5 kg, was brought to Teaching & Training Pet Hospital and Research Center (TTPHRC), Dhaka. To minimize the cat's aggressiveness and prevent reproduction, the owner decided to spay it. The spaying procedure was carried out using a typical open surgical approach with general anesthesia. The operation went well, and the cat was advised to be kept in a clean squeeze cage for seven days to observe. It was also suggested that povidone iodine ointment will be used as antibacterial until it healed completely. There were no difficulties during the follow-up of the patient. This surgical process for spaying in cat was incredibly simple, affordable, and very effective.

Keywords: spaying, cat, traditional surgical technique

Chapter 1: Introduction

The female reproductive tract is completely removed during an ovariohysterectomy (OHE), sometimes known as spaying. Spaying not only prevents the animal from becoming pregnant, but it also prevents the animal from going into heat twice a year. The source of manufacturing hormones (estrogen and progesterone) involved with the estrous cycle and pregnancy is removed through surgery. The most crucial surgery involved with appropriate pet care is spaying. Every pet, with the exception of animals used solely for breeding or displaying, should be spayed. To avoid an unexpected pregnancy, any pet with access to the outdoors should be spayed or neutered.

Ovariohysterectomy (OHE) is the most commonly performed on companion animals such as dogs and cats. According to World Atlas, the global cat population is about 400 million, or 10% of the human population. Seventy-five percent of these can be classified as owned dogs. Bangladesh has a livestock population of 4221.80 lakh, with approximately 25 million cats and an estimated 80% stray cat population. Ovariohysterectomy (OVH) is an irreversible technique that is used for the sterilization of female animals (Kirsan et al., 2013) where surgery was done under proper general anesthesia and sterile operating technique (Virginia et al., 2012). This is usually done by a small incision on her left hand side and can also be done underneath along her midline (Machado et al., 2012). Spaying is done for the prevention of reproduction and making docile the animal. It is also done to protect them from certain diseases (Janssens and Janssens, 1991). Spaying is the most common among elective surgeries (Pollari and Bonnett, 1996).

Before a cat reaches sexual maturity and is capable of having kittens, it is suggested that they be spayed. This usually occurs between the ages of four and six months. Spaying can be done using either a typical open procedure or a laparoscopic approach. Because laparoscopic surgical equipment is expensive, the open approach of spaying is extensively used. A caudal midline incision below the umbilicus is commonly used for traditional open surgery. The size of the incision depends on the surgeon and the size of the animal. The ovaries are detected by following the uterine horns to their ends and identifying them.

Some studies were carried out on the spaying of cats in Bangladesh previously (Azizunnesa et al., 2017). However, further study is needed to know more detail with improved techniques on spaying of cat. Therefore, this case report is planned to

execute and evaluate the traditional surgical technique of spaying of cat and make it as a strong tool of birth control.

Objective:

1. To perform and evaluate the traditional surgical technique of spaying in cat.
2. To identify the pre and post anesthetic hazards of spayed bitch.

Chapter 2: Materials and Method

2.1 Case history and description:

A local breed female cat of 8 months old having 2.5 kg body weight was brought to Teaching & Training Pet Hospital and Research Center (TTPHRC), Dhaka. It was very aggressive to handle and the owner wants to stop the reproduction as there is a scarcity of place in her house. The owner wanted to do spay the cat to reduce its aggressiveness and to prevent reproduction. General examination revealed that it had a fair body condition with a respiratory rate 20/min (normal), heart rate 175 beats/min(normal), no dehydration and pink mucous membrane. No blood tests or ultrasonography was not done in this case.

2.2 Anesthesia and control:

Both physical and chemical methods were used to control the cat. Pre-anesthetic xylazine (1 mg/kg body weight) was given to relax and sedate the patient. The surgical site was aseptically prepared for the operational procedure after the proper clipping and shaving.

As fluid therapy, the animal was given regular saline intravenously. As a general anesthetic, a 1:4 mixture of Diazepam and Ketamine hydrochloride was delivered intravenously.

2.3 Operation procedure:

First of all, we made a plan of treatment before starting the procedure. We wanted to ensure the safety of the cat. So we keep a very close eye on the hygiene and pain management procedure. We use a general surgical pack after sterilizing it at 121 degree Celsius. We gave proper anesthesia and we ensure the maintaining dose properly and we maintained the sterile environment throughout the operation. A 1 cm incision was made 2 fingers below the umbilicus in the caudal midline. Incisions were made in the skin, subcutaneous tissue, muscle, and peritoneum in that order. The surgeon's index finger was introduced toward the left flank into the abdominal cavity, uterine horn, and broad ligament to remove it outside the incision after all layers were completed.

Between the thumb and index finger, the ovary was grabbed and extracted for ligation. Manual traction with the finger burst the ovary's suspensory ligament. The ovarian connection and its blood vessels were exposed by making a wide incision in the broad ligament with fingers. To ligate the ovarian pedicle, a double chromic catgut ligation was utilized. The ligature's and the ovary's attachments were severed.

Following the removal of one ovary, another was found and removed in the same manner. The uterus's body was removed from the abdomen. On each side, the uterine vessels were ligated and divided. The uterine stump was then thoroughly examined to rule out bleeding. The peritoneum, muscles, and fascia were all sutured separately using 1-0 catgut in a simple continuous suture pattern. The skin was then sutured with horizontal mattress sutures with non-absorbable nylon suture material, followed by sub cuticular suture with 2-0 catgut.

2.4 Post-operative treatment and care:

After surgery, antibiotic ceftriaxone @ 20mg/kg body weight (Ceftron IM 250mg) was administered intramuscularly for 5 days. Antihistaminic pheniramine maleate @

0.5 mg/kg bwt (Alerin 10ml) was administered intramuscularly for 5 days.

Analgesic meloxicam @ 0.2 mg/kg bwt (Melvet 10ml) was administered subcutaneously for 3 days. The animal was suggested to keep in a clean squeeze cage and to observe for 7 days. The owner was suggested to provide antiseptic povidone iodine ointment on the incision site until complete healing.

The full operation went as we planned. Proper hygiene and sterility of the OT room was maintained throughout the operation. The animal became fully well after 14 days of the operation.

Chapter 3: Results and Discussion

Result:

The operation went well because the cat recovered quickly from anesthesia and there were no difficulties. There was no more bleeding discovered. After recovering anesthesia and receiving a prescription of giving treatment with systemic antibiotics for the next five days, she was discharged home.

Discussion:

Spaying an animal can restrict reproduction and make it docile, according to a previous study (Janssens and Janssens, 1991). It may also aid in the prevention of uterine infection, uterine cancer, and other reproductive system malignancies. The owner of this cat wanted to spay it to lessen its aggressiveness and prevent reproduction in this study.

The procedure is performed under general anesthesia. Hair is trimmed from the abdomen, which is then surgically cleansed. In the case of dogs and cats, a tiny incision is made along the midline, where there are fewer blood veins (Jason, 2009). The same procedure was used in this investigation when it came to spaying.

The uterus and uterine horns are located using a general surgical pack. The uterus and ovaries are totally removed, and the blood vessels are closed up. The outside skin layer was closed after the interior body wall was sutured with absorbable suture material. In this investigation, the same approach was used.

The operation was effective, and it was comparable to those carried out by Janssens and Janssens (1991); Azizunnesa et al. (2017).

In previous investigations, postoperative spaying problems in cats and dogs were discovered (Pollari and Bonnett, 1996 and Pearson, 1973). There is less pain as the proper anesthetic procedure and analgesic treatment given as per L. S. Slingsby et al.(1998). However, no problems or further bleeding were observed in this trial.

Chapter 4: Conclusion

Spaying a cat is a classic surgical procedure that has been found to be the most effective. It was a simple, practical, field-tested, and reliable method for cat spaying. There were no difficulties throughout the follow-up of the spayed cat in this investigation. Spaying is a conventional surgical procedure that can be used to diminish the aggressiveness of a field condition and inhibit reproduction. To make the technique easier, more research is recommended.

Figures

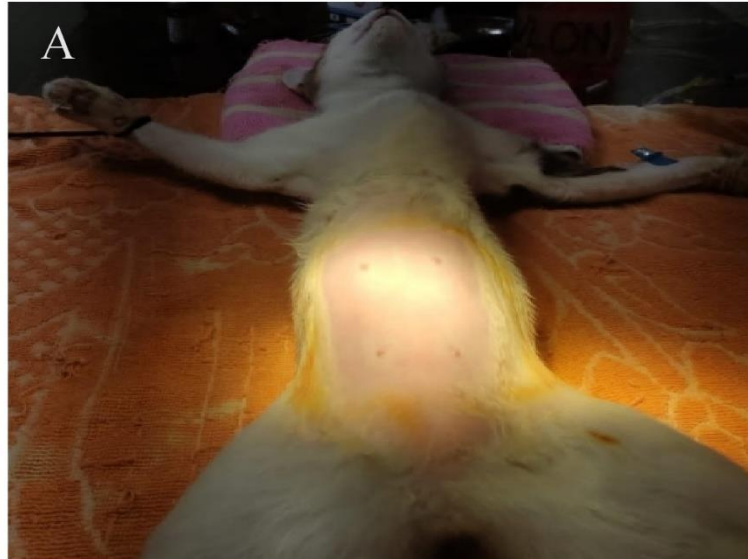


Figure A: The surgical site was shaved properly. The region was demarcated from the upper portion of umbilicus to the pelvic. The umbilicus was used as a landmark. After shaving, povidone iodine and alcohol were used properly to sterilize the incision area.

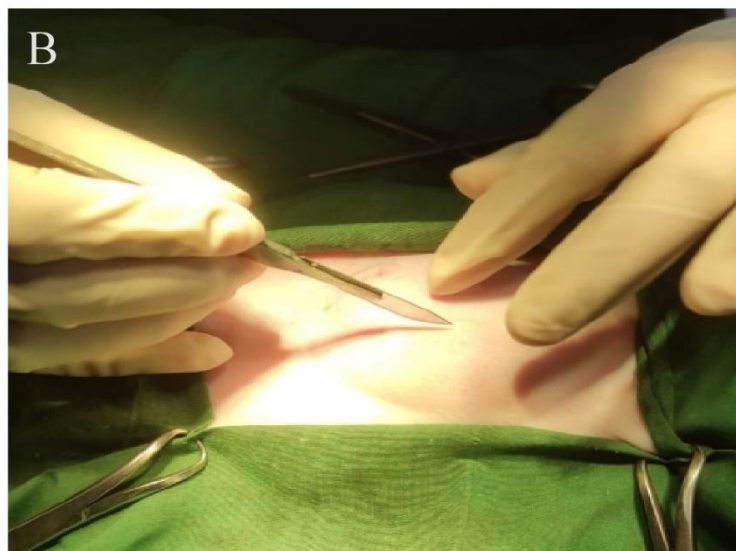

Figure B: The draper were properly placed and clipped with towel clamps followed by incision. A mid line incision around 2-3 cm behind the umbilicus was performed. The bleeding was checked by applying gauge pressure and artery forceps.

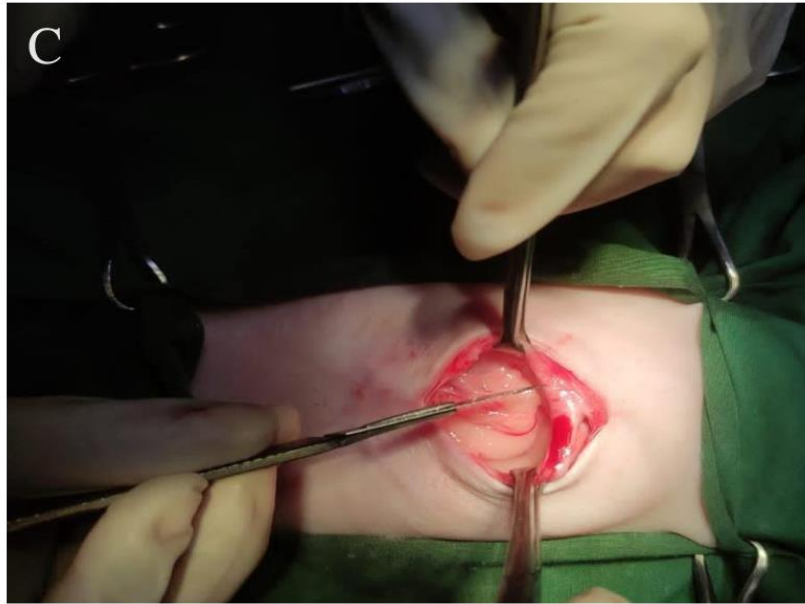


Figure C: A careful incision was made through the mid line of the body to prevent the unwanted muscle cutting. After incision on the muscle, the two parts were pulled in two sides using Allis's forceps where that peritoneum remain intact.

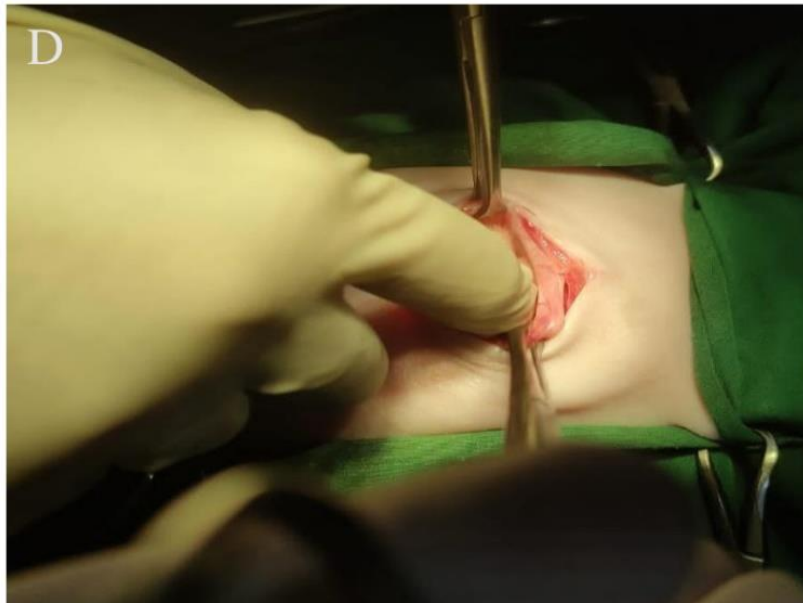


Figure D: Peritoneum was cut cautiously. Then a finger was introduced into the peritoneum to locate and pull out ovaries. The uterine horns were identified by fingers and ovaries were found following the horn to their ends.

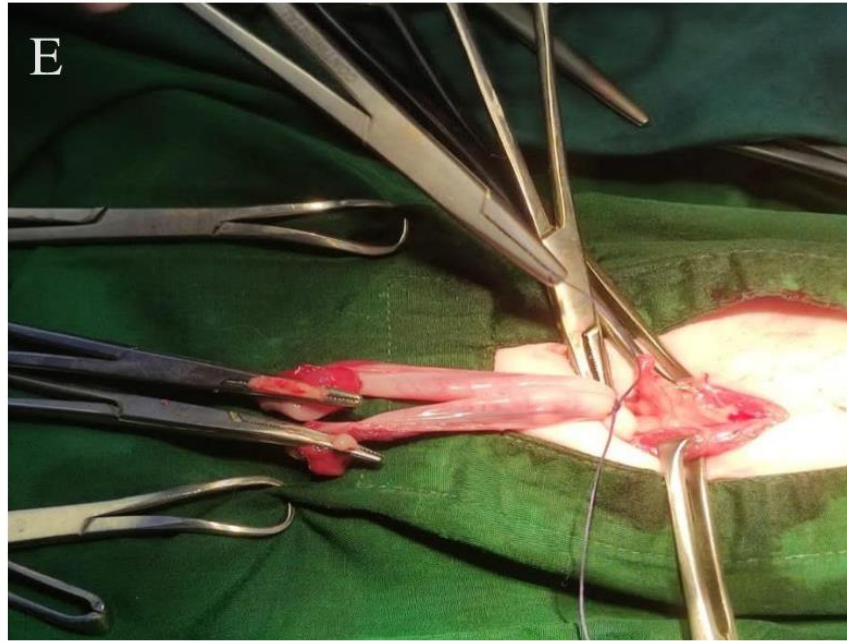


Figure E: Using the finger, we located one ovary. Then two ligations were used in the vascular and avascular part after passing the ovary. The ovaries were excised using artery forceps and scalpel. Then uterine body was removed after suturing of the uterine body.

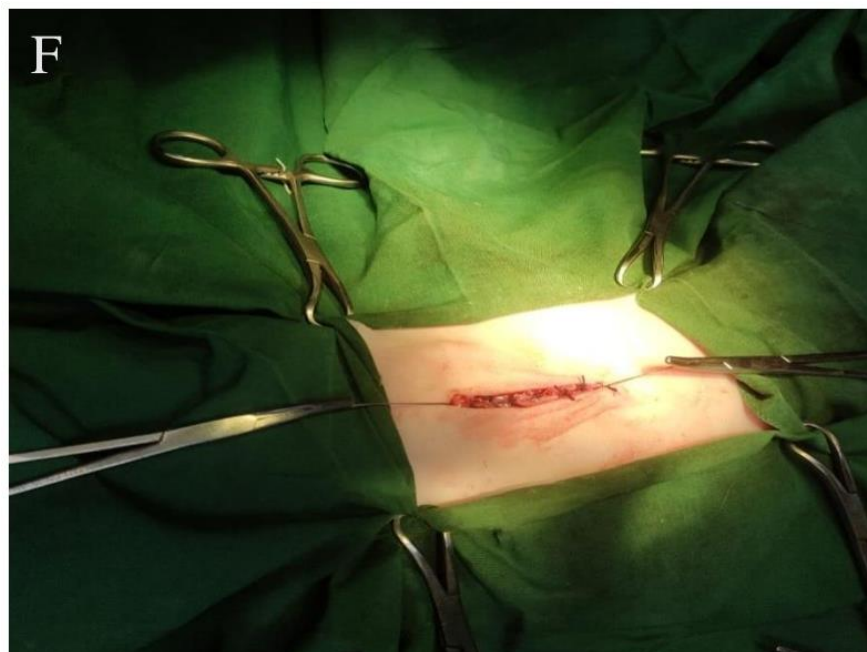


Figure F: After cutting the uterine body, the rest were push back into the peritoneum. The peritoneum and muscle layers were sutured with simple continuous pattern with catgut (1-0). The subcutaneous layer was sutured with subcuticular pattern using catgut (1-0). The skin was sutured using simple interrupted suture using Nylon.

References

- Azizunnesa, Hossain, D., Chaudhary, P., Parvez, M.A., Paul, P., Yadav, S.K., Hasan, T. (2017). Spaying as a tool for birth control: A case report. *Res. J. Vet. Pract.* 5(2): 19-24.
- Janssens, L.A.A., Janssens, G.H.R.R. (1991). Bilateral flank ovariectomy in the dog- surgical technique and sequelae in 72 animals. *J. Small Anim. Pract.* 32: 249-252.
- Kirsan, I., Enginler, S. O., Toydemir, T.S.F., Erzençin, O.M., Sonmez, K., Sennazl, G. (2013). Gynaecological complications following improper ovariohysterectomy in a dog. *Int. J. Vet. Sci.* 2 (4):121-124.
- Slingsby, L.S., Waterman-Pearson, A.E. (1998). Comparison of pethidine, buprenorphine and ketoprofen for postoperative analgesia after ovariohysterectomy in the cat. *Veterinary Record* (1998) 143, PP-185-189.
- Machado, S.M.A., Toniolloll, K.G.H., Freitas, C.C.D., Veloso, B.C.Q.M. (2012). Pure-transvaginal natural orifice transluminal endoscopic surgery (NOTES) ovariohysterectomy in bitches: a preliminary feasibility study. *Ciência Rural.* 42(7): 1237-1242.
- Pearson, H. The complications of ovariohysterectomy in the bitch. *J Small Anim Pract.* 1973 May 14(5):257-266
- Pollari, F.L., Bonnett, B.N. (1996). Evaluation of postoperative complications following elective surgeries of dogs and cats at private practices using computer records. *Canadian Vet. J.* 37: 672-678.
- Virginia, H.P, Adriano, B.C, Carlize, L., Martiello, I.G., Daniel, C.M.M., Clarissa, D.G (2012). Epidural anesthesia and postoperative analgesia with alpha-2 adrenergic agonists and lidocaine for ovariohysterectomy in bitches. *Canadian J. Vet. Res.* 76: 215-220.

Acknowledgments

The author wishes to acknowledge the immeasurable grace and profound kindness of Almighty “**KRISHNA**” the supreme authority and supreme ruler of the universe, who empowers the author to complete the work successfully.

It is deemed as a proud privilege and extra-terrestrial pleasure to express author ever indebtedness, deepest sense of gratitude, sincere appreciations, profound regards to the reverend and beloved teacher and supervisor **Dr. Bibek Chandra Sutradhar**, Professor, Department of Medicine and Surgery, Chattogram Veterinary and Animal Sciences University for his ingenuous and scholastic guidance, judicious recommendations, constant inspiration, continuous encouragement and valuable suggestions to report writing have guided the author from the beginning of the inception of intern studies until to the completion of this report.

The author would like to express his gratefulness to Professor **Dr. Mohammad Alamgir Hossain**, Dean, FVM, CVASU and Professor **Dr. A.K.M. Saifuddin** and staff of Department of Medicine and Surgery.

The author is ever indebted to his parents for their sacrifices, blessing and encouragement to get him in this position. It's also to be ungrateful, if not express the deep sense of gratitude to all of his friends, roommates, and well-wishers for their help, encouragement and inspiration during the study period.

The author,
November,
2021.

Biography

I am Sattajeet Chakraborty, son of Sudhan Chakraborty and Bina rani Chakraborty. I passed Secondary School Certificate Examination in 2012 from Chattogram Collegiate High school followed by Higher Secondary Certificate Examination in 2014 from Chattogram College. Now I am an intern veterinarian under the Faculty of Veterinary Medicine in Chattogram Veterinary and Animal Sciences University. In the future, I would like to work as a veterinary practitioner and do research on clinical animal diseases in Bangladesh.